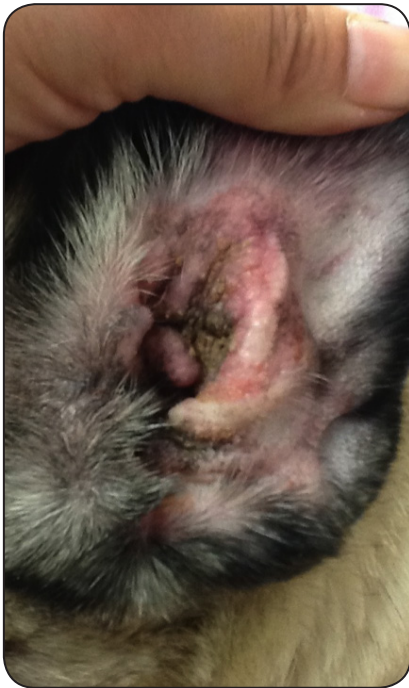

CASE CONTEST: OTITIS

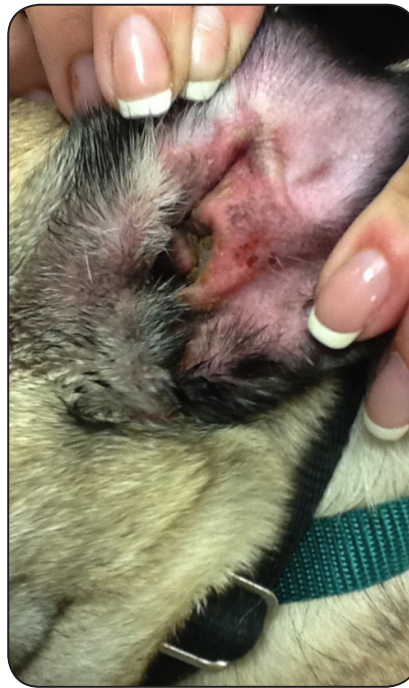Woodland Springs Veterinary Hospital, Ft. Worth, Texas

Species and Breed	10 year old, M/N Mixed Breed Dog, 30 lbs
Presentation	Left ear very inflamed and the canal was swollen with yellow debris. Visual inspection with otoscope; ear cytology revealed bacterial and yeast otitis.
Treatment Details	307.5 total joules administered to superficial component and 690 total joules delivered to deep component at 3.5W; Frequency of two treatments, two consecutive days. Appropriate topical therapy was used as well.
Treatment Results	Otitis resolved with ear much less swollen and pruritic after treatment.

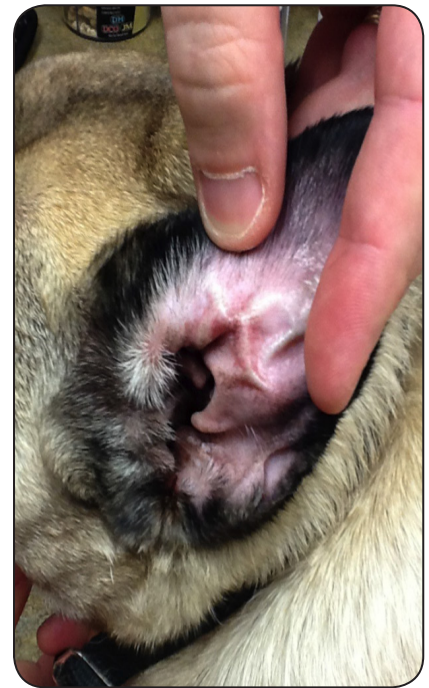
Photos and case courtesy of Woodland Springs Veterinary Hospital, Ft. Worth, Texas



Day 1- 10/16



Day 2



Day 14