

A SPECIAL ADVERTISING SECTION

Injured Donkey Responds to Laser Therapy

By Jean Heaton Lovell
For The Education Series

Donkey Boy was a miniature Sicilian donkey, mature and intact, with all the characteristic grouchiness found in that species. What he lacked in size, he made up for in stubborn will. He was so ornery that you couldn't help but love him.

Matthew Lovell, DVM, an equine practitioner in middle Tennessee, was initially called to see Donkey Boy because he was down, in pain and wasn't passing manure. The equine was dragging his left hind leg and appeared weak and ataxic in the back end. He was treated with non-steroidal anti-inflammatories and dexamethasone.

Dr. Lovell passed a nasogastric tube and gave him oil, water and electrolytes. The next day Lovell was called back to see Donkey because the animal had still not passed manure. His abdomen was distended and he was still weak behind. His previous treatment was repeated with the addition of DMSO per NG tube.

On the third day, the owners gave Donkey an enema. He passed manure that was very hard and dry. Lovell gave him a high enema, which produced some soft balls. This finally provided some relief and Donkey was happy to enjoy a few handfuls of grass.

The owners experienced many ups and downs during the 10 days. They decided to bring Donkey to the clinic for a full workup to get a diagnosis. By then, no bowel movements had occurred in two to three days. Again, his abdomen was distended, but now his lung sounds were harsh.

He was tubed, given an enema and lab work was performed. The next day he began to pass manure and was becoming more comfortable, so digital X-rays were taken. Standing oblique radiographs showed pelvic fractures. The tuber coxae, wing and body of the ilium were shattered.

Over the next five to six days, Donkey Boy was a pretty sick fellow. He was monitored by blood work, and an ultrasound was performed on his lungs to check for pneumonia. He was treated for his inability to pass manure, given antibiotics for the harsh lung sounds, and administered Gastrogard, electrolytes and anti-inflammatories for the swelling in the pelvis.

At that point the folks from Companion Therapy Lasers brought a Class IV therapy laser to Lovell's clinic for a demonstration. Lovell, who has been in practice for 26 years, was fairly new to many of the complementary therapies. If it can't be tested, meas-



Donkey Boy, a miniature Sicilian donkey like these, was Dr. Lovell's first laser therapy patient.

ured, or proven in black and white, then he is likely to be a skeptic.

After the demonstration, Kathy from Companion Therapy wondered if he had a case that the laser could be used on. Because it was supposed to be so beneficial in reducing swelling and pain, Donkey was an obvious choice.

Donkey was standing stoically in his stall as the group entered the clinic's barn. The

During the wait, Donkey failed to progress. NG treatments and enemas were given, Gastrogard, flax seed oil, neostigmine and antibiotics were administered. Every day brought more and more concern.

laser was set up, and in typical Donkey fashion, he dragged himself to the back corner of his stall, showing the group just how much he appreciated the company.

Kathy told Lovell where she would focus the laser light, the number of Joules she would use and showed him some acupuncture points that she would target. She told him that Donkey would probably get restless, move around and then pass manure and urinate. Because several days had passed since he had produced manure, and each time he did was preceded by treatments involving nasogastric tubing and high enemas, Lovell politely said OK.

A few minutes passed, and just as she had predicted, Donkey scooted around the stall and produced not one or two but many piles of manure. He then urinated. It was as if a miracle had occurred. Lovell was sold and ordered a therapeutic laser system that day.

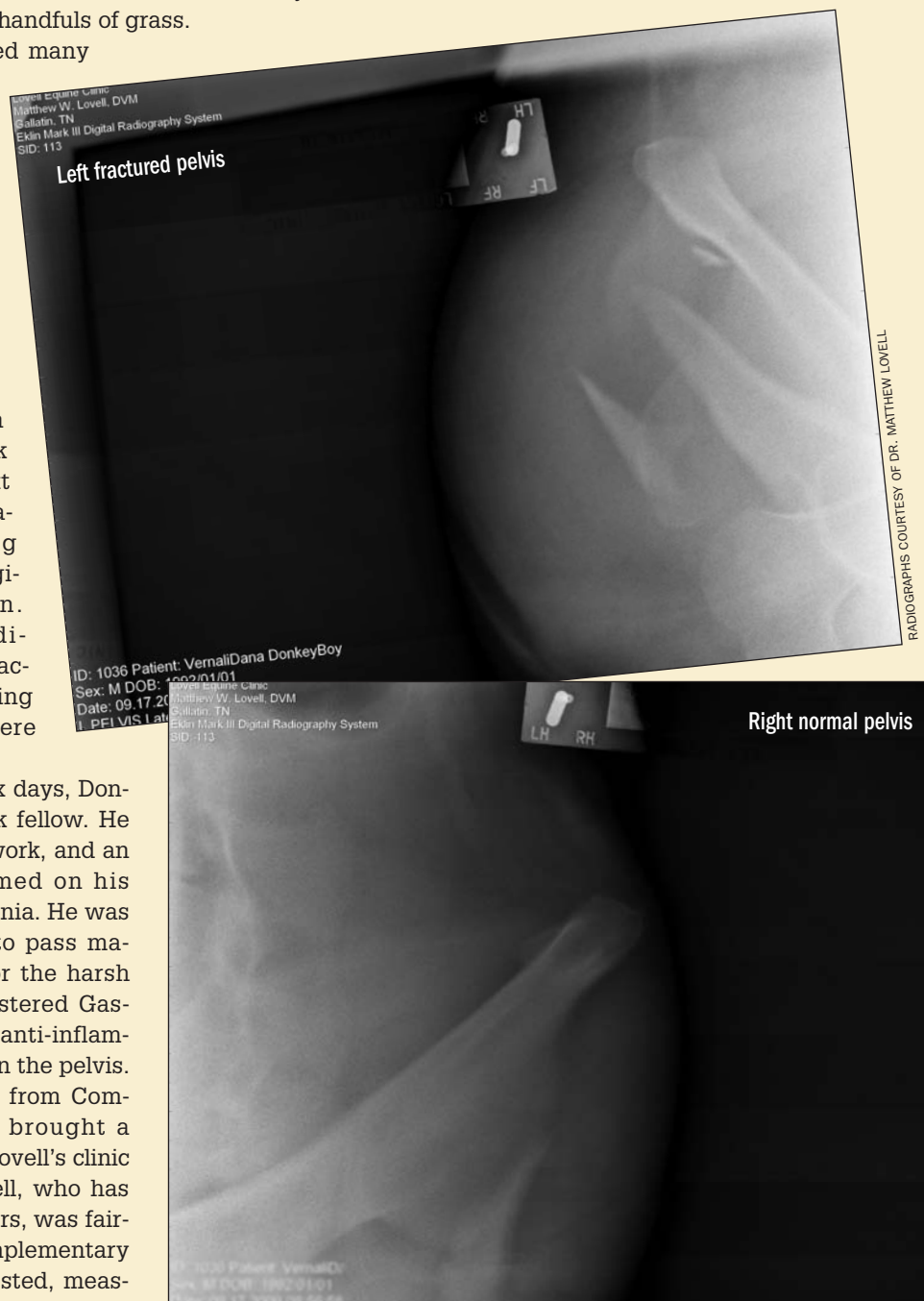
Because of the demand for the laser unit at the time, the unit didn't arrive for 10 days. During the wait, Donkey failed to progress. NG treatments and enemas were given, Gastrogard, flax seed oil, neostigmine and antibiotics were administered. Every day brought more and more concern.

Finally, the unit arrived and a regimen of treatments was prescribed. Each treatment seemed to bring noticeable relief. Over the next 30 days, Donkey received 12 laser treatments. Donkey began to associate the rolling of the laser cart with something pleasant. He would back up to the stall door as it was being wheeled in.

After six weeks, he was released from the clinic and received a few more treatments at home. Donkey Boy went back to the farm to keep his eye on the girls, where he lived out the rest of his days. ●

Matthew Lovell, DVM, owns Lovell Equine Clinic in Gallatin, Tenn. He is a graduate of Ohio State University's College of Veterinary Medicine. He is a member of the American Veterinary Medical Association, the American Association of Equine Practitioners and the Tennessee Veterinary Medical Association, which he serves as a board member.

Jean Lovell is a graduate of Western Kentucky University in Bowling Green. After working for almost 20 years in her husband's equine practice, she has begun a new chapter as a freelance writer.



RADIOGRAPHS COURTESY OF DR. MATTHEW LOVELL

This Education Series story was underwritten by Companion Therapy Laser of Newark, Del.