

A special advertising section

PRP for multiple shoulder tendinopathies

By Andrew Armitage, BSc, BVM&S, MRCVS
For The Education Center

Domino, a 6-year-old neutered male boxer, presented to Greenside Veterinary Practice in St. Boswells, Scotland, for thoracic limb lameness. Domino had a six-month history of chronic right forelimb lameness that became worse after exercise and rest. The lameness did not respond to exercise restriction or NSAIDs.

There was marked supraspinatus muscle atrophy, and a positive biceps test on physical examination and flexion of the shoulder resulted in moderate discomfort. Radiographs revealed mild shoulder osteoarthritis, with a small osteophyte on the caudal aspect of the humeral head. There were signs of the start of osteophyte formation in the bicipital groove and increased soft tissue density in the region of the bicipital tendon and supraspinatus tendon.

The radiographic changes were very mild and could not account for the severity of lameness seen, so further investigation using musculoskeletal ultrasound was performed on the shoulder joint and supporting structures. Ultrasound examination revealed severe disruption in the fiber pattern of both the bicipital tendon and the supraspinatus tendon, with areas of diffuse fibrosis and calcification.

The extent of the changes seen on ultrasound could explain the severity and chronic nature of the lameness. This shows how important appropriate diagnostics are to localize the lesion so a proper treatment plan can be initiated.

A diagnosis was made of chronic bicipital tendonitis with a concurrent supraspinatus tendinopathy. This diagnosis could have been missed if the only diagnostic tool used was radiography.

Domino was placed on a static stance analyzer to measure weight distribution between all four limbs. A normal dog carries 60 percent of its weight on the forelimbs and 40 percent on the hind limbs, with equal distribution between the left and the right. Although the 60:40 weight distribution is normal for most dogs, some breeds differ slightly from normal.

On initial examination, the stance analysis showed a reduction in weight bearing in the right thoracic limb, and this was being transferred to his left thoracic limb and his right pelvic limb, causing unequal weight distribution across the body. It can be seen in this table:

DOMINO'S STANCE ANALYSIS

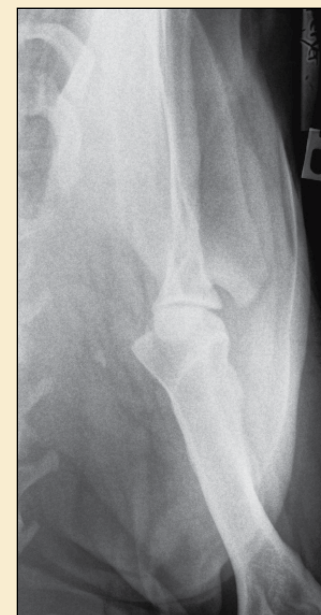
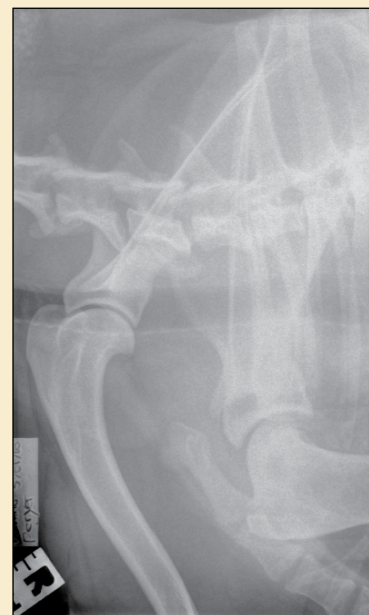
VISIT	LEFT FRONT	RIGHT FRONT	LEFT REAR	RIGHT REAR	WEIGHT (POUNDS)
Before treatment	37%	29%	15%	19%	75.36
6 weeks after treatment	34%	34%	17%	15%	79.29

After various treatment possibilities were discussed with the owner, platelet-rich plasma (PRP) was agreed upon. However, if PRP alone did not result in resolution of the lameness, the next stage would be to combine PRP with stem cell therapy.

PRP, with a platelet concentration of five times that of normal blood, was prepared using the Companion Therapy CRT system. Autologous PRP was then injected into the affected regions of the supraspinatus and bicipital tendon using ultrasound guidance. One milliliter of



A stance analysis is performed using a four-quadrant mat.



Representative images depicting arthritic shoulder and osteophyte formation

PRP also was injected into the shoulder joint after aspiration of the joint fluid.

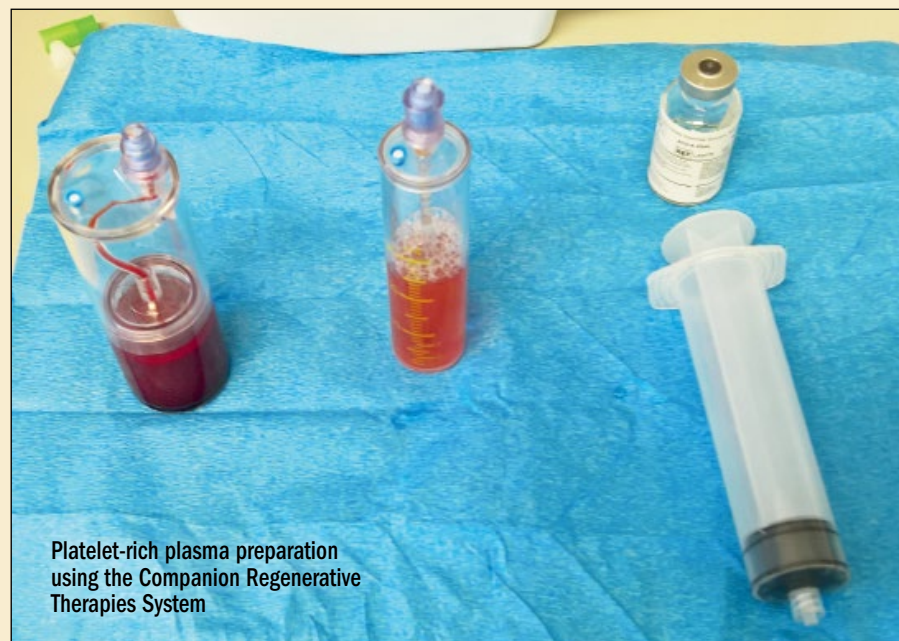Domino's NSAIDs were stopped before he received the injections, and he was sent home on a short course of paracetamol and codeine analgesia and was rested for two weeks.

Short-lead exercise was started after two weeks and was slowly built up over six weeks. At the six-week check-up, Domino showed no signs of lameness but still exhibited mild stiffness after rest that quickly resolved on exercise.

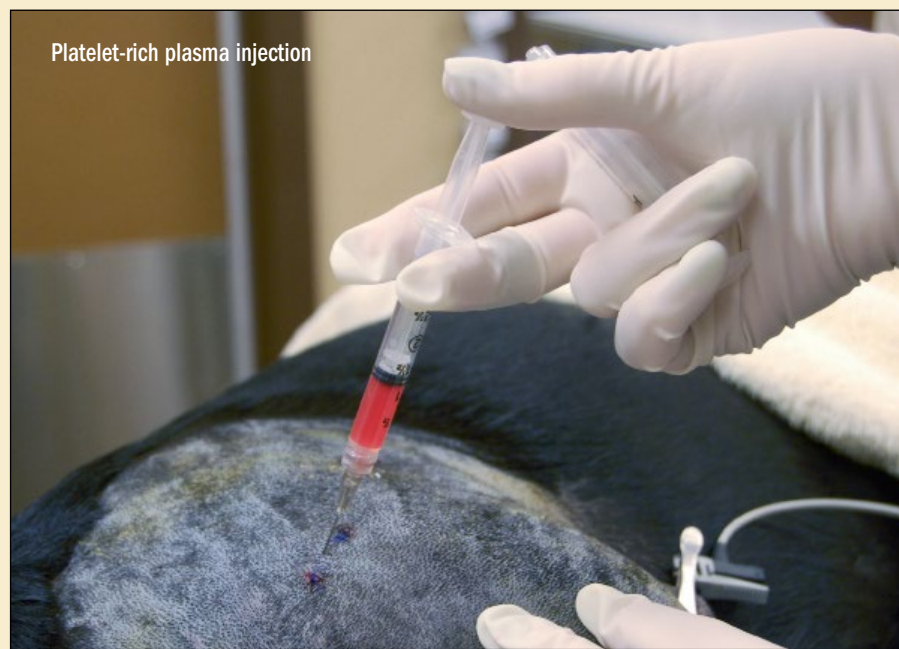Repeat ultrasound showed remodelling of both tendons, with reduction in fibrosis and restoration of a more normal fiber pattern.

A stance analysis showed equal weight distribution between both thoracic limbs, and there was no pain on the bicipital test. Domino is a very front-heavy boxer and carries more weight forward than dogs of different breeds, hence the increased weight bearing seen by the stance analysis in the forelimbs in relation to the hind limbs.

Six months after treatment, Domino was exercising normally, displayed no lameness or stiffness, and was not receiving any pain medication. ●



Platelet-rich plasma preparation using the Companion Regenerative Therapies System



Platelet-rich plasma injection

Dr. Andrew Armitage is a partner at Greenside Veterinary Practice in St. Boswells, Scotland. His special interests include advanced regenerative therapy techniques. He is particularly interested in investigating the use of Class IV laser therapy and regenerative medicine for acute and chronic conditions.

This Education Center article was underwritten by Companion Animal Health of Newark, Delaware.