

## A CASE STUDY

# Putting Shine on Titan's Golden Years

By Dennis Arp  
Contributing Editor

Every day, the weight of Titan's 12 years seemed to exact a new toll. And the German shepherd wasn't the only one toting the burden of his decline.

His owner, Rachael Carlson, felt for her beloved pet as he suffered through one infection after another and struggled with pain and inflammation in his aging joints.

"His anal sacs were always infected and had bloody secretions," Carlson says. "He was constantly on antibiotics, and we had to go see our veterinarian over and over. Plus, he was having a difficult time getting on the bed and couch, and he fell down a lot.

"We were considering euthanasia."

That seems eons ago, Carlson says, though it's been just 18 months since a reprieve first surfaced via a concerted and consistent approach to Titan's treatment featuring Class IV laser therapy. Safe to say, his improvement has fed the quality-of-life meter for both dog and owner.

"Our intent was simply to help Titan be more comfortable," Carlson says. "We've gotten much more than that."

Here is a closer look at the role therapeutic laser played in improving the quality of an aging pet's life.

### Patient

Titan, an 81-pound, 12-year-old neutered male German shepherd.

### Problem

Sanguineous, purulent and fetid discharge from the anal sacs in addition to bilateral hip dysplasia and subluxation of the left coxo-femoral joint.

John Godbold, DVM, owner and operator of Stonehaven Park Veterinary Hospital in Jackson, Tenn., took on Titan as a referral patient in early 2009. The dog's anal sacculitis had persisted for years despite treatment that included repeated expression of the anal sacs, local infusion of antibiotics and systemic use of anti-inflammatories.

In addition, Titan's left elbow joint was markedly enlarged and arthritic, Dr. Godbold says, with a limited range of motion. Carlson indicated that Titan had been on nonsteroidal anti-inflammatories with limited response but now was being treated with glucosamine-chondroitin supplements only.

It was clear, Carlson says, that a new course of action was needed.

### Treatment Plan and Procedure

After an initial consultation and exam, Godbold was confident he could help Titan's chronic anal sacculitis using Class IV therapy laser treatment because he had seen it get results in previous cases. He also recommended concurrent laser treatment of

the dog's arthritic joints. "Our experience, and that of hundreds of our colleagues in both veterinary and human clinical laser therapy, indicated we could have a positive impact on Titan's quality of life," Godbold says.

After consulting with the referring veterinarian, whom Godbold emphasized continues to provide routine care for Titan, the dog began a course of seven therapy laser treatments, which were administered twice a week, with a re-evaluation at the seventh treatment.

### Therapy Laser Settings

Titan's anal sacs and perianal area were treated with 600 Joules CW and 300 Joules 10,000 Hz (target dose 9 Joules per centimeter squared). Each hip was treated with 1,500 Joules CW (target dose 10 J/cm<sup>2</sup>) from a dorsolateral direction and 300 Joules CW from a ventral direction (target dose 10 J/cm<sup>2</sup>). His left elbow was treated with 1,200 Joules CW, applying the treatment from 360 degrees (target dose 10 J/cm<sup>2</sup>).

### The Plan in Action

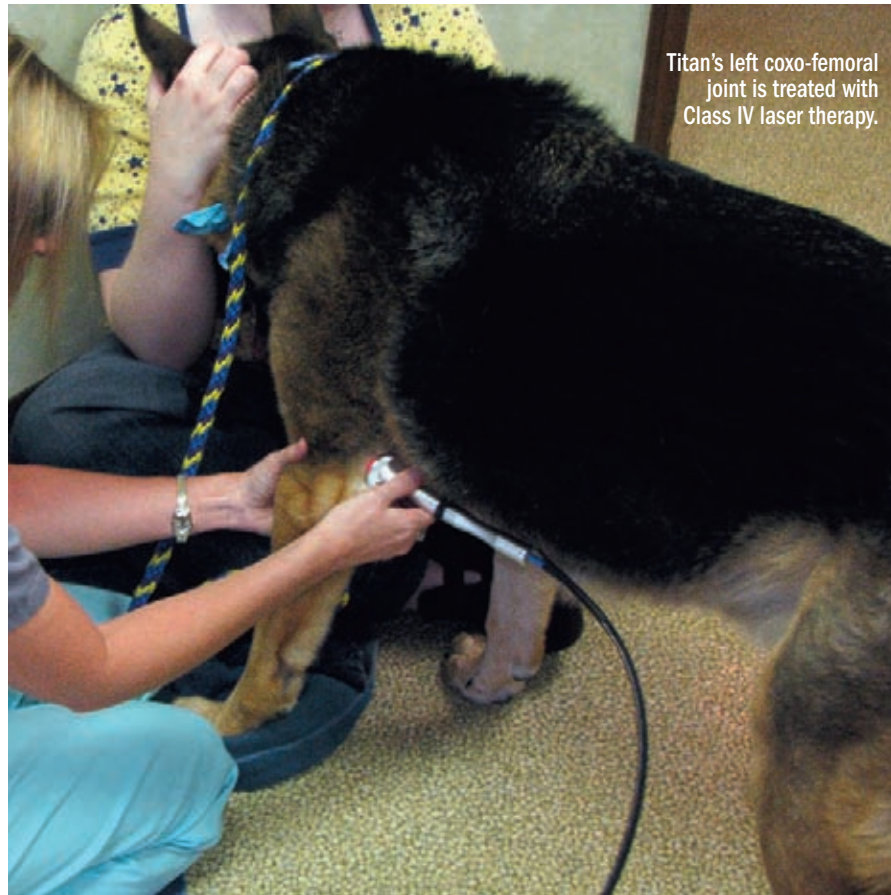
After the initial seven treatments, Godbold noted that the anal sac secretions had returned to normal color, odor, volume and consistency, and Carlson reported that Titan was non-symptomatic at home. What's more, Titan was significantly more mobile and navigated her home's slick floor surfaces with greater ease.

Carlson had previously worked as a veterinary technician, so Godbold knew he could trust her observations. He recommended a maintenance course of laser treatments—every 14 to 21 days, depending on what Carlson reported on Titan's response at home.

"Since beginning maintenance therapy, we've treated Titan over 40 times—an average of every 10 days," Godbold says. "That's more frequently than usual with our arthritis patients, indicating how severe Titan's degenerative joint disease is."

At about \$40 per treatment, it also indicates Carlson's commitment to laser therapy.

"We made every effort to get the treatments more spaced out, just for the economics and the benefit of scheduling for the owner, but ultimately she was the one who said, 'We need to do this (about every 10 days),' " Godbold says. "She's a very conscientious owner."



Titan's left coxo-femoral joint is treated with Class IV laser therapy.

PHOTO COURTESY OF DR. JOHN GODBOLD

### Results

Everyone involved in managing Titan's anal sacculitis noted that inflammation, irritation, obsessive licking and fetid secretions ceased to be a problem, Godbold says. The effect on Titan's aging and diseased joints also was positive.

"The whole family could see how much better Titan was able to get around after we started treating his arthritis with the laser," Carlson says.

Laser therapy isn't a cure, however.

"We must be prepared to adjust our treatments as our patients continue to age," Godbold says.

A year into managing Titan, he began treating the dog's lumbar spine for arthritic changes and arthritis-related stenosis. Treatments of his lumbar spine and muscles deliver 2,400 Joules CW (target dose 10 J/cm<sup>2</sup>).

"Even though Titan's arthritis has now become more advanced," Carlson adds, "the extra 18 months we've had with him have just been icing on the cake."

### Epilogue

Titan became a joy to treat, technicians Jennifer Donaldson and Tami Mitchell say. Titan developed a fondness for the warming sensation and release of tissue endorphins each session brought.

Once the cumulative effects of his pain relief took hold, he also warmed to a new activity: chasing the aiming beam as it danced around the treatment room floor.

"We haven't stopped Titan's aging process," Godbold says. "We didn't expect to. But we do take pleasure in laser therapy having put a little shine on his golden years." ●

*This Education Series article is underwritten by LiteCure LLC of Newark, Del.*